



Endometriosis: seeking optimal management in women approaching menopause

L. Alio, S. Angioni, S. Arena, L. Bartiromo, V. Bergamini, N. Berlanda, V. Bonanni, C. Bonin, L. Buggio, M. Candiani, G. Centini, M. N. D'Alterio, F. De Stefano, A. Di Cello, C. Exacoustos, L. Fedele, M. P. Frattaruolo, E. Geraci, E. Lavarini, L. Lazzeri, S. Luisi, A. Maiorana, S. Makieva, F. Maneschi, F. Martire, C. Massarotti, A. Mattei, L. Muzii, J. Ottolina, L. Pagliardini, A. Perandini, F. Perelli, I. Pino, M. G. Porpora, V. Remorgida, G. Scagnelli, R. Seracchioli, E. Solima, E. Somigliana, G. Sorrenti, A. Ticino, R. Venturella, P. Viganò, M. Vignali, F. Zullo & E. Zupi

To cite this article: L. Alio, S. Angioni, S. Arena, L. Bartiromo, V. Bergamini, N. Berlanda, V. Bonanni, C. Bonin, L. Buggio, M. Candiani, G. Centini, M. N. D'Alterio, F. De Stefano, A. Di Cello, C. Exacoustos, L. Fedele, M. P. Frattaruolo, E. Geraci, E. Lavarini, L. Lazzeri, S. Luisi, A. Maiorana, S. Makieva, F. Maneschi, F. Martire, C. Massarotti, A. Mattei, L. Muzii, J. Ottolina, L. Pagliardini, A. Perandini, F. Perelli, I. Pino, M. G. Porpora, V. Remorgida, G. Scagnelli, R. Seracchioli, E. Solima, E. Somigliana, G. Sorrenti, A. Ticino, R. Venturella, P. Viganò, M. Vignali, F. Zullo & E. Zupi (2019): Endometriosis: seeking optimal management in women approaching menopause, *Climacteric*, DOI: [10.1080/13697137.2018.1549213](https://doi.org/10.1080/13697137.2018.1549213)

To link to this article: <https://doi.org/10.1080/13697137.2018.1549213>



Published online: 10 Jan 2019.

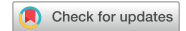

Submit your article to this journal [↗](#)










View Crossmark data [↗](#)

REVIEW



Endometriosis: seeking optimal management in women approaching menopause

L. Alio^a, S. Angioni^b, S. Arena^c, L. Bartiromo^d, V. Bergamini^e, N. Berlanda^{f,g} , V. Bonanni^h, C. Bonin^e, L. Buggio^g , M. Candiani^d, G. Centiniⁱ, M. N. D'Alterio^b, F. De Stefano^d, A. Di Cello^j, C. Exacoustos^k, L. Fedele^{f,g} , M. P. Frattaruolo^g , E. Geraci^l, E. Lavarini^e, L. Lazzeriⁱ, S. Luisiⁱ, A. Maiorana^a, S. Makieva^m, F. Maneschiⁿ, F. Martire^k, C. Massarotti^{o,p} , A. Mattei^q, L. Muzii^h, J. Ottolina^d, L. Pagliardini^m, A. Perandini^e, F. Perelli^r, I. Pino^s, M. G. Porpora^h, V. Remorgida^{o,p}, G. Scagnelli^s, R. Seracchioli^t, E. Solima^s, E. Somigliana^{f,g} , G. Sorrenti^k, A. Ticino^h, R. Venturella^j, P. Viganò^m , M. Vignali^s, F. Zullo^u and E. Zupi^k

^aDepartment of Obstetrics and Gynecology, Civic Hospital, Palermo, Italy; ^bDepartment of Surgical Sciences, University of Cagliari, Cagliari, Italy; ^cDepartment of Obstetrics and Gynecology, Azienda Ospedaliera Perugia, Perugia, Italy; ^dGynecology Department, IRCCS San Raffaele Scientific Institute, Milan, Italy; ^eDepartment of Obstetrics and Gynecology, Azienda Ospedaliera Universitaria Integrata, Verona, Italy; ^fDepartment of Clinical Sciences and Community Health, Università degli Studi di Milano, Milan, Italy; ^gGynaecology Unit, Fondazione IRCCS Ca' Granda Ospedale Maggiore Policlinico, Milan, Italy; ^hDepartment of Gynecology, Obstetrics and Urology, 'Sapienza' University of Rome, Rome, Italy; ⁱDepartment of Molecular and Developmental Medicine, Obstetrics and Gynecology, University of Siena, Siena, Italy; ^jDepartment of Clinical and Experimental Medicine, Obstetrics and Gynecology, Università degli Studi Magna Graecia, Catanzaro, Italy; ^kDepartment of Biomedicine and Prevention, Università degli studi di Roma 'Tor Vergata', Rome, Italy; ^lDepartment of Obstetrics and Gynecology, Asola Hospital, Mantova, Italy; ^mDivision of Genetics and Cell Biology, IRCCS San Raffaele Scientific Institute, Milan, Italy; ⁿDepartment of Obstetrics and Gynecology, San Giovanni Addolorata Hospital, Roma, Italy; ^oAcademic Unit of Obstetrics and Gynaecology, Ospedale Policlinico San Martino, Genoa, Italy; ^pDepartment of Neurosciences, Rehabilitation, Ophthalmology, Genetics, Maternal and Child Health (DiNOGMI), University of Genoa, Genoa, Italy; ^qDepartment of Minimally Invasive Gynaecological Surgery, Centre Tuscany USL, Florence, Italy; ^rDepartment of Experimental, Clinical and Biomedical Sciences, Obstetrics and Gynaecology, University of Florence, Florence, Italy; ^sDepartment of Obstetrics and Gynecology, University of Milan, Macedonio Melloni Hospital, Milan, Italy; ^tGynecology and Physiopathology of Human Reproductive Unit, University of Bologna, S. Orsola-Malpighi Hospital of Bologna, Bologna, Italy; ^uDepartment of Neuroscience, Reproductive Sciences and Dentistry, School of Medicine, University of Naples Federico II, Naples, Italy

ABSTRACT

The incidence of endometriosis in middle-aged women is not minimal compared to that in the reproductive age group. The treatment of affected women after childbearing age to the natural transition toward menopause has received considerably poor attention. Disease management is problematic for these women due to increased contraindications regarding hormonal treatment and the possibility for malignant transformation, considering the increased cancer risk in patients with a long-standing history of the disease. This state-of-the-art review aims for the first time to assess the benefits of the available therapies to help guide treatment decisions for the care of endometriosis in women approaching menopause. Progestins are proven effective in reducing pain and should be preferred in these women. According to the international guidelines that lack precise recommendations, hysterectomy with bilateral salpingo-oophorectomy should be the definitive therapy in women who have completed their reproductive arc, if medical therapy has failed. Strict surveillance or surgery with removal of affected gonads should be considered in cases of long-standing or recurrent endometriomas, especially in the presence of modifications of ultrasonographic cyst patterns. Although rare, malignant transformation of various tissues in endometriosis patients has been described, and management is herein discussed.

ARTICLE HISTORY

Received 17 May 2018
Revised 29 October 2018
Accepted 2 November 2018
Published online 11 January 2019

KEYWORDS

Perimenopause; endometriosis; middle-aged women; management; endometriosis treatment; endometriosis malignant transformation

Introduction

Endometriosis has traditionally been considered a disease of the reproductive years. The prevalence of the disease seems to be ~5%, with a peak between 25 and 35 years of age¹. As an estrogen-dependent disease, it tends to undergo regression after menopause. Indeed, Punnonen *et al.*² describe a frequency of 2.2% for postmenopausal endometriosis. Current literature on endometriosis addresses justifiably

specific management concerns of reproductive age women, including infertility and pelvic pain. Data on postmenopausal disease, although more limited and largely confined to case reports and retrospective studies, have some space in the current literature. Conversely, there has so far been a notable lack of interest for the treatment options of affected women after childbearing age to the natural transition toward menopause.

Table 1. WHO Medical Eligibility Criteria (MEC)¹⁹ revised for women with endometriosis and modified according to age-related important cardiovascular risk factors.

	Age 18–40 years	Age ≥40 years
No cardiovascular risk factors	COC ^a , R ^a , POP ^a , LNG-IUD ^a	POP ^a , LNG-IUD ^a , COC ^b , R ^b
Body mass index ≥30	POP ^a , LNG-IUD ^a , COC ^b , R ^b	POP ^a , LNG-IUD ^a , COC ^b , R ^b
Smoking		
<15 cigarettes/day	R ^a , POP ^a , LNG-IUD ^a , COC ^b	POP ^a , LNG-IUD ^a , R ^b
≥15 cigarettes/day	R ^a , POP ^a , LNG-IUD ^a , COC ^b	POP ^a , LNG-IUD ^a
Hypertension	POP ^a , LNG-IUD ^a	POP ^b , LNG-IUD ^b
>2 cardiovascular risk factors including vascular diseases	POP ^b , LNG-IUD ^b	POP ^b , LNG-IUD ^b

COC, combined oral contraceptives; LNG-IUD, levonorgestrel intrauterine device; POP, progestogen-only pill; R, vaginal ring.

^aMEC category 1: method can be used in any circumstances.

^bMEC category 2: method can be generally used.

According to an estimation of the Icelandic population between 1981 and 2000, using Iceland's extensive record linkage systems in which each case of visually diagnosed and histologically verified endometriosis was cross-checked against the nationwide pathology registry, age-specific incidence in the age groups 30–34, 35–39, and 40–44 years was estimated at 13.4, 13.3, and 13.2/10,000 person-years, respectively. For the age group 45–49 years it was only slightly lower, being around 12/10,000 person-years during the latter half of the study period (1991–2000)³. In a retrospective German epidemiological study, a descriptive analysis of 42,079 women undergoing surgical treatment due to histologically confirmed endometriosis in the period 2005–2006 was carried out. The premenopausal group (age 0–45 years) was represented by 80.36% of the patients, while 7191 patients (17.09%) belonged to the perimenopausal group (age 45–55 years). A total of 16,969 patients (40.33%) admitted to hospital and treated for endometriosis were over the age of 40 years⁴.

Thus, although the incidence of endometriosis appears high in perimenopause, surprisingly the interest toward this category of affected women has been marginal. The topic was addressed for the first time in 1993 by Witt and Barad⁵ with a review aimed at discussing the management of endometriosis in women older than 40 years, with a distinct focus on women still requiring childbearing and on menopausal women. No other contribution can be appreciated in the literature. However, women in the transitional time between reproductive life and menopause represent a population facing unaccustomed issues while treating disease-associated pain symptoms and preventing recurrences. Some of these include the increased risk of medical contraindications to combined hormonal contraceptive (COC) use and the risk of malignant transformation of the disease considering that the cancer risk markedly increases in women who have a long-standing history of the disease⁶.

On these bases, the aim of this state-of-the-art review is to gain insight into the benefits and safety of the various therapies for endometriosis that can help guide treatment decisions for the care of women approaching menopause.

Onset of natural menopause in endometriosis

Few data are available regarding the age at menopause of women with endometriosis. The majority of evidence argues that surgical treatment of ovarian endometriomas impairs

ovarian reserve⁷, hence earlier occurrence of menopause in affected women must be considered. Coccia *et al.*⁸ conducted a longitudinal prospective cohort study to investigate the age of menopause in patients who underwent surgery for endometriosis. Unfortunately, out of the 302 evaluated patients the mean age of menopause was only recorded for 43 women, which should not be considered a representative number. Additionally, a high percentage of women with premature ovarian failure (16.3%) was observed, the majority of whom were submitted to ovarian cystectomy for bilateral endometriomas. This underlies the need for a well-designed study addressing menopausal age in endometriosis, presently absent in the literature.

It is not clear whether endometriosis per se can influence the onset of menopause. Ovarian endometriomas contain many potentially toxic agents that may diffuse through the cyst wall and impact the ovarian reserve⁹.

Other factors could interfere with the age at menopause of endometriosis women. A reduced body mass index has been associated with an early age at menopause, probably in relation to reduced estrogen production by the adipose tissue. A lower body weight is considered a risk factor for endometriosis as well¹⁰. On the other hand, the use of high-dose COCs seemingly advances the onset of menopause by approximately 1.2 months for every year of COC use compared with no COC use¹¹. Given the impact of natural menopause on the management of endometriosis women, the ability to predict ovarian reserve in terms of distance to menopause would be extremely important. Some of the benefits would include reducing the surgery rate in women with menopause approaching in less than 2 years or allowing clinicians to plan the best long-term management strategy for those with ovaries predicted to be active for many years ahead. A long-term treatment balancing between safety and recurrence prevention should be envisaged also in women approaching menopause.

This overview has considered evidence collected from middle-aged women excluding those known to have previously undergone a natural or iatrogenic menopause.

Recommendations from the international guidelines on endometriosis

The international guidelines on endometriosis have not proposed precise recommendations for treatment of women approaching menopause, probably due to the lack of

Table 2. Cases of acute bowel obstruction due to endometriosis in middle-aged women: literature review.

Author, year	Number of patients	Age (years)	Location	Symptoms	Type of endometriosis	Management
Collins, 1957 ³²	2	(1) 40 (2) 48	Ileum and ileocecal valve Sigmoid	Colicky abdominal pain, vomiting Lower abdominal colicky pain, constipation, diarrhea	SBE + PE LBE + OE + PHE	Ileum resection and ileocecal anastomosis + appendicectomy Sigmoid resection and colorectal anastomosis + appendicectomy + TAH (years before)
Scalvini, 1959 ³³	1	47	Ileum	Intermittent abdominal pain, biliar vomiting, abdominal distension	SBE	Ileal resection and end-to-end anastomosis
Midorikawa et al., 1997 ³⁴	1	42	Rectum	Lower abdominal pain	LBE + PE	Low anterior resection and TAH
Fujimoto et al., 2001 ³⁵	1	46	Ileocecal junction	Nausea, vomiting, abdominal distention	OE + PE + SBE	GnRH-a for 3 months TAH + BSO
Almendolara et al., 2001 ³⁶	1	45	Sigmoid	Abdominal pain	LBE + PE	Anterior resection and colorectal anastomosis + myomectomy
Mussa et al., 2001 ³⁷	1	42	Ileum	Diarrhea, bloating and abdominal pain protein-losing enteropathy, anasarca	SBE	Ileum resection + appendicectomy
Kupersmith et al., 2001 ³⁸	1	42	Sigmoid (fecal peritonitis secondary to a perforated cecum)	Abdominal pain, cramps, anorexia	LBE + PHE + OE + PE	Anterior resection and temporary colostomy
Varras et al., 2002 ³⁹	1	43	Sigmoid	Abdominal pain, symptoms of bowel occlusion	LBE + PE	Resection of descending and sigmoid colon + left oophorectomy
Sheikh et al., 2005 ⁴⁰	1	42	Ileocecal junction	Abdominal pain, diarrhea alternating with constipation, vomiting, poor appetite	SBE	Ileocolonic resection
Yldirim et al., 2005 ⁴¹	1	46	Rectosigmoid junction	Vomiting and colicky abdominal pain	LBE	Low anterior resection + temporary colostomy
De Ceglie et al., 2008 ⁴²	1	44	Distal ileum	Abdominal pain, diarrhea alternating with constipation	SBE/LBE	Right hemicolectomy
Mourthè de Alvim Andrade et al., 2008 ⁴³	2(1)	40	Rectum	Abdominal pain	LBE + PE	Rectosigmoidectomy + colostomy
Ruiz et al., 2008 ⁴⁴	1	41	Ileocecal valve	Cramping abdominal pain, diarrhea alternating with constipation, vomiting	SBE	Ileal resection + ileocolic anastomosis
de Jong et al., 2009 ⁴⁵	5(1)	43	Ileum	Nausea, vomiting, generalized abdominal pain and/or distention	SBE + PE	GnRH-a Laparotomy: - Colostoma - Bilateral ureter stents Anterior resection + anastomosis
Caselli et al., 2011 ⁴⁶	1	44	Sigmoid colon and the rectosigmoid junction	Hypogastric pain, abdominal cramps	LBE + OE + PE	
Unalp et al., 2012 ⁴⁷	1	45	Ileocecal valve	Abdominal pain, nausea, vomiting	SBE	Unknown
Khawaja et al., 2012 ⁴⁸	1	44	Terminal ileum	Colicky central abdominal pain, bilious vomiting, diarrhea	LBE	Right hemicolectomy
Soylu et al., 2012 ⁴⁹	2	(1) 42 (2) 45	Cecum and sigmoid Cecum	Abdominal pain, nausea	LBE + PHE LBE + PHE	Right hemicolectomy Right hemicolectomy
Lanitis et al., 2013 ⁵⁰	1	40	Rectosigmoid junction	Abdominal pain, constipation, bilious vomiting	LBE + OE	Sigmoid and upper-rectum resection + right adnexectomy
Azizad-Pinto and Clarke, 2014 ⁵¹	1	48	Right-sided catamenial pneumothorax Distal sigmoid colon	Non-thoracic symptoms Abdominal symptoms: left-sided abdominal pain; non-bloody, non-bilious emesis; alternating diarrhea, constipation	LBE + catamenial pneumothorax	Rectosigmoid resection, appendectomy, diverting loop ileostomy, TAH + BSO
Arafat et al., 2016 ⁵²	1	50	Rectosigmoid junction	Constipation and abdominal cramps	LBE + PHE	Sigmoidectomy and colostomy + TAH + BSO
López Carrasco et al., 2017 ⁵³	2	(1) 41	Rectosigmoid junction	Chronic pelvic pain, pseudo-obstruction symptoms	LBE + OE + PHE	Ileum and rectosigmoid resection + TAH + BSO, partial colectomy
Chan et al., 2017 ⁵⁴	1	(2) 41 46	Ileum Distal ileum	Catamenial pseudo-obstruction Vomiting, abdominal distention, absolute constipation	SBE + OE + PE SBE	Ileum resection + right adnexectomy, myomectomy Small bowel resection + end-to-end anastomosis

BSO, bilateral salpingo-oophorectomy; LBE, large-bowel endometriosis; OE, ovarian endometriosis; PE, pelvic endometriosis; PHE, previous endometriosis history; SBE, small-bowel endometriosis; TAH, total abdominal hysterectomy.

Table 3. Clinical characteristics of endometriosis of the central and peripheral nervous system in middle-aged women: literature review.

Author, year	Number of patients	Age (years)	Location	Symptoms	Type of endometriosis ^a	Management
Richards <i>et al.</i> , 1991 ⁵⁸	1	46	Sciatic nerve	W, SL	Extra	Surgery, danazol
Zager <i>et al.</i> , 1998 ⁵⁹	1	45	Sciatic nerve	P, W, SL	Intra-extra	Surgery (biopsy and external neurolysis), GnRH-a, TAH BSO
Vilos <i>et al.</i> , 2002 ⁶⁰	3	41, 41, 40	Peritoneal endometriosis (n = 2), pelvic peritoneal pocket (n = 1)	P	Extra	Laparoscopic excision
Lacroix-Triki <i>et al.</i> , 2004 ⁶¹	1	50	Sciatic nerve	P, W	Intra-extra	TAH BSO, excision of pelvic endometriotic pockets, CT, GnRH-a, palliative RT
Fatemi <i>et al.</i> , 2005 ⁶²	1	55	Lumbosacral plexus	P	Extra	Aromatase inhibitors
Nagra <i>et al.</i> , 2010 ⁶³	1	45	L5-S1 spinal nerves	P	Intra-extra	Not reported
Floyd <i>et al.</i> , 2011 ⁶⁴	1	44	Sciatic nerve, gluteal nerve	P, W, SL	Intra-extra	Neurolysis, GnRH-a
Ceccaroni <i>et al.</i> , 2011 ⁶⁵	1	41	Sacral plexus, pudendal nerve, sciatic nerve	P, W, SL	Extra	Neurolysis
Ghezzi <i>et al.</i> , 2012 ⁶⁶	1	45	Sciatic nerve	P, W	Extra	GnRH-a
Siquara De Sousa <i>et al.</i> , 2015 ⁶⁷	1	49	Sciatic nerve, L5-S1 spinal nerves	P, W, SL	Intra	Hormonal treatment
Capek <i>et al.</i> , 2016 ⁶⁸	1	45	Sciatic nerve	P, SL, W	Intra-extra	TAH BSO, neurolysis
Arányi <i>et al.</i> , 2016 ⁶⁹	2	50, 46	Sciatic nerve (n = 2)	P, SL (n = 1); P, W, SL (n = 1)	Intra-extra (n = 2)	GnRH-a (n = 1), not available (n = 1)
Sarma <i>et al.</i> , 2004 ⁷⁰	1	40	Cerebellar vermis	Gait disturbance, headache	Not available	Surgical excision
Agrawal <i>et al.</i> , 2006 ⁷¹	1	40	Conus medullaris	P, W, SL	Intra	D12-L2 laminectomy danazol, BSO

BSO, bilateral salpingo-oophorectomy; CT, chemotherapy; GnRH-a, gonadotropin-releasing hormone agonist; P, pain; RT, radiotherapy; SL, sensory loss; TAH, total abdominal hysterectomy; W, weakness.

^aIntra, intraneural endometriosis (i.e. confined to the nerve); intra-extra, intraneural-extraneural endometriosis (i.e. infiltrating the nerve as well as extending outside the nerve); extra, extraneural endometriosis (i.e. outside the nerve, described as extrinsically 'compressing' or being 'attached' to the nerve).

evidence. Some recommendations have been generated for women who have completed their family planning with a persistent and unresponsive symptomatology. The American College of Obstetricians and Gynecologists¹² proposes hysterectomy, with bilateral salpingo-oophorectomy, as the definitive treatment for endometriosis associated with intractable pelvic pain, adnexal masses, or multiple previous conservative surgical procedures in women who do not desire fertility preservation and in whom conservative medical and surgical management has failed. The efficacy of definitive surgery coupled with ovarian conservation has been questioned based on evidence indicating that the relative risk for recurrence of pain after total abdominal hysterectomy was 6.1 (95% confidence interval 2.5–14.6) higher compared with women who have their ovaries removed. The relative risk of additional surgery was 8.1 (95% confidence interval 2.1–31.3) with ovarian conservation¹³. On the contrary, in a more recent contribution, patients who underwent endometriosis excision and hysterectomy and were monitored for a median duration of 7.6–11 years did not require reoperation with or without oophorectomy¹⁴.

The 2014 European Society for Human Reproduction and Embryology guidelines recommend considering definitive surgery (hysterectomy with bilateral oophorectomy, together with the removal of all visible lesions) for women who completed their reproductive arc and have a persistence of symptoms despite medical therapy¹⁵. However, they also recommended informing the patients that hysterectomy would not necessarily cure disease symptoms. A similar recommendation has been proposed by the Society of Obstetricians and Gynecologists of Canada¹⁶.

The World Endometriosis Society consensus on current management of endometriosis has declared that recommendations were related to reproductive age women but underlined that the role of hysterectomy and of concurrent oophorectomy represents a matter of debate with little reliable evidence to inform practice¹⁷.

According to the National Institute for Care and Health Excellence¹⁸, if hysterectomy is indicated for other reasons, all visible lesions should be excised at the time of the hysterectomy and the women should be informed about the risks and benefits of the intervention.

Use of hormonal drugs in middle-aged women affected by endometriosis

The use of hormonal drugs in women older than 40 years of age raises concerns in the gynecological community with regards to their safety. Perimenopausal women are at higher risk for the development of unwanted side effects related to the administration of hormones compared to younger women. Therefore, guidelines on the topic have been published and are continuously reviewed, in order to reduce the onset of potentially dangerous complications¹⁹. In general terms, no hormonal method is contraindicated solely on the basis of age. However, in most developed countries, the general middle-aged population is at risk of cardiovascular disorders or various cancer types, including breast, endometrial,

Table 4. Cases of malignant transformation of bladder/neurological/thoracic endometriosis in middle-aged women: literature review.

Author, year	Number of patients	Age (years)	Type of endometriosis	Location and histological type of tumor	Symptoms and previous HoE	Diagnosis	Management and recurrence
Balat <i>et al.</i> , 1996 ⁷⁴	1	40	BE Right ovary endometriosis	Bladder clear cell adenocarcinoma invading rectum	Low back pain, proctorrhagia No previous HoE	MRI/TC Colonoscopy	Anterior resection of the rectum, partial cystectomy and right adnexectomy, CT (carboplatin)
Mann <i>et al.</i> , 2012 ⁷⁵	1	54	BE	Bladder endometrioid adenocarcinoma	Gross hematuria, irregular menses No previous HoE	Pelvic US TURBT	TAH BSO, partial cystectomy, pelvic LND and anterior vaginal wall resection
Tarumi <i>et al.</i> , 2015 ⁷²	1	45	BE	Bladder endometrioid carcinoma	Urinary incontinence, Miction pain Previous HoE	Pelvic US MRI	TAH, partial cystectomy, ureteral stents, CT (docetaxel/carboplatin)
Miller <i>et al.</i> , 2016 ⁷⁶	1	44	BE	Bladder clear cell adenocarcinoma	Urinary incontinence, Urinary infections and hematuria No previous HoE	Pelvic US, cystoscopy, TURBT	No recurrence TAH BSO, pelvic LND, anterior exenteration, ileal conduit, CT (carboplatin + paclitaxel)
Yu <i>et al.</i> , 2013 ⁸³	1	45	TE	Central-type lung cancer	No previous HoE	CT	No recurrence at 6 months Lobectomy No recurrence
Lacroix-Triki <i>et al.</i> , 2004 ⁶¹	1	50	NE	Low-grade endometrial stroma of sciatic nerve	Left buttock mass and motor deficit Previous HoE	MRI	TAH BSO, excision of pelvic endometriotic pockets, CT, GnRH-a, palliative RT

BE, bladder endometriosis; BSO, bilateral salpingo-oophorectomy; CT, chemotherapy; GnRH-a, gonadotropin-releasing hormone agonist; HoE, history of endometriosis; LND, lymph node dissection; MRI, magnetic resonance imaging; NE, neurological endometriosis; RT, radiotherapy; TAH, total abdominal hysterectomy; TC, computed tomography; TURBT, transurethral resection of the tumor; US, ultrasound.

ovarian and gastrointestinal cancers. Therefore, the use of hormonal compounds could become a reason for concern. We refer to the WHO Medical Eligibility Criteria (MEC)¹⁹ for recommendations on the hormonal treatments to use in the case of women aged 40 years or older with or without cardiovascular risks or severe hypertension.

In patients with endometriosis, safety represents a very important issue because patients may need long periods of treatments even during advanced reproductive years. Progestins (norethisterone acetate or dienogest) have been proven effective in reducing various types of pain including dysmenorrhea and dyspareunia and, belonging to MEC category 1, should be preferred in perimenopausal women (Table 1). As far as the progesterone-only pill is concerned, persistent bleeding is a common finding, not occurring with combined contraception. Vaginal bleeding in perimenopausal women requires further investigation in order to exclude all other gynecological pathologies that more commonly manifest above 40 years of age. Therefore, additional costs and invasive procedures, namely hysteroscopy, may be required, and could even be considered as additional side effects in the case of progesterone-only treatment. Low-dose oral norethisterone acetate is probably the best choice for rectovaginal lesions²⁰. COCs, belonging to MEC category 2, can be generally used cyclically or continuously in women with low risks and constitute an adequate first-line option for peritoneal and ovarian endometriosis¹⁹. This hormonal therapy is also effective to reduce the risk of recurrences of these lesions, above all on endometrioma reformation after surgical excision²¹. In patients with painful endometriosis close to menopause, considering the side effect of COCs, gonadotropin releasing hormone agonist (GnRH-a) should be cited, unsuitable for the long term but very effective in reducing pain in the short term²².

As far as the risk for cancer is concerned, women who have used COC for prolonged periods for ovarian endometriomas should be informed that they are simultaneously protected from an increase in the risk of endometriosis-associated ovarian cancer. According to Modugno *et al.*²³, the use of COCs for >10 years is associated with 80% reduction in risk. After the early forties, however, unilateral oophorectomy plus bilateral salpingectomy could be the best risk-reducing approach, as this would imply not only prevention of endometrioid and clear cell tumors, but also of high-grade serous ones¹. The use of hormonal drugs increases the risk of developing cervical cancer, but this risk is counterbalanced by the compliance of women to the national screening programs for this disorder. Less clear data regard breast cancer but, again, screening and routine clinical examinations are able to decrease the potential minimal risk induced by the hormonal treatment¹⁹.

Hormone replacement therapy in women with surgical-induced menopause for endometriosis

Some reviews have addressed the use of hormone replacement therapy (HRT) in postmenopausal women with endometriosis^{24,25} but postmenopause is not the focus of this

article. On the other hand, middle-aged women might receive surgical treatment leading to a surgical-induced menopause. Women should not be denied HRT treatment simply because of a history of endometriosis as there is a general consensus that the benefits of its use would far outweigh its risks, particularly in women with an early natural or surgical menopause¹⁵. Moreover, there appears to be no reason to delay starting HRT after surgery²⁴. A full and frank discussion with the patient should be held about the risks and benefits of this treatment. The risk for malignant transformation of endometriotic tissue is increased in women with residual disease after surgery. Unopposed estrogen might carry the highest risk; it may be safer to give either continuous combined estrogen-progestogen therapies or tibolone as the risk of recurrence may be reduced²⁵.

Methods

Information for this review was identified by searches of Medline and PUBMED and references from relevant articles from inception until March 2018 using combinations of the MESH terms 'endometriosis' OR 'endometriosis management' OR 'endometriosis medical treatment' OR 'endometriosis malignant transformation' OR 'endometriosis-associated cancer' OR 'endometriosis-associated tumor' OR 'endometriosis surgery' with 'perimenopause' OR 'middle-aged women'. The search was limited to peer-reviewed, full-text articles in the English language. Three authors (P.V., J.O., L.B.) reviewed the articles and discrepancies were resolved by consensus. The eligibility of the studies was firstly based on titles and abstracts. Full manuscripts were obtained for all selected papers and decision for final inclusion was made after detailed evaluation of the articles. Abstracts accepted in conferences were excluded from the review.

Management of urinary tract endometriosis in middle-aged women

Bladder endometriosis

Contradictory data are reported about the optimal treatment (medical or surgical) in bladder endometriosis in women older than 40 years of age. Westney *et al.*²⁶ reported excellent results in 14 patients with bladder endometriosis treated with either low-dose COC or progestins: 92% of patients reported partial or complete resolution of symptoms with a median follow-up of 18.6 months. The mean age of this cohort of patients was 48.7 years, with 78.6% of patients being older than 40 years²⁶.

Others claimed that both the symptoms associated with bladder endometriosis and the lesion itself may respond suboptimally to medical therapies due to the desmoplastic reaction within the detrusor resulting from repetitive bleeding and consequent continuous local insult²⁷. Recurrence might be an issue in this context. Conversely, possible complications related to the surgery should not be underestimated in patients approaching menopause. Indeed, if endometriosis lies very close to the trigone, surgical excision can cause

postoperative neurogenic bladder. Moreover, in about 10% of the women, vesicovaginal fistulas have been described²⁸. Importantly, since the lesions might be associated to other deep localizations, surgery tends to be performed in conjunction with other high-risk procedures such as bowel surgery^{28,29}.

Thus, according to the limited evidence, hormonal treatments (COCs and progestogens) may not cure but seem to be effective in temporarily suppressing bladder endometriosis in women with an impending menopause²⁹. In any case, patients should be informed that the disease may progress after medical treatment, so regular follow-up is advisable. For patients with contraindications to hormonal therapies or who refuse the medication but experience pain despite medical treatment, surgical excision of bladder endometriosis should be performed.

Ureteral endometriosis

Treatment of ureteral endometriosis is primarily surgical²⁷. The surgical treatment aims to relieve ureteral obstruction and avoid recurrence. It should be tailor-made, from ureterolysis to ureteroneocystostomy or ureteral resection with end-to-end anastomosis, depending on the extent of the ureteral infiltration, the location of the lesion, and the conditions of the ureter after ureterolysis³⁰. Moreover, hysterectomy with or without bilateral salpingo-oophorectomy may be considered in women with obstructive ureteral disease older than 40 years who have completed childbearing. Hysterectomy should be combined with the removal of any other endometriotic implants, especially deep lesions often associated with ureteral endometriosis¹⁸. It should be underlined that with ovarian conservation, 27% of patients will need additional surgery for recurrent pelvic pain, whereas only 3% of patients undergoing hysterectomy and oophorectomy will require reoperation¹⁴.

Management of bowel endometriosis in middle-aged women

Benign symptomatic bowel endometriosis

In women with known intestinal endometriosis, the perimenopausal years pose a challenge due to persistence of pain, reactivation, or malignant degeneration, even in women with prior surgery³¹. Women previously operated for bowel endometriosis approaching menopause with no signs of recurrence and a good control of symptoms with medical therapy should continue hormonal therapy in use, if not contraindicated. Surgery, on the other side, is generally performed for obstructive lesions and for treatment of refractory pain³¹. The patient should be aware that definitive surgery will not necessarily cure the disease, since cases of bowel endometriosis that occurred after surgical menopause are reported in the literature in about 14% of cases¹⁴.

Bowel endometriosis presenting as acute bowel occlusion

Although rare, acute bowel obstruction is a serious complication of bowel endometriosis, more commonly found in women presenting with rectosigmoid involvement and requiring emergency surgery. Table 2 reports the cases of acute bowel occlusion presenting in perimenopausal women with endometriosis^{32–54}, most of them occurring without a previous diagnosis of the disease. The acute event has been preceded by bowel symptomatology such as constipation or diarrhea in some cases, not necessarily correlated to menses. Because malignant transformation cannot be excluded preoperatively and medical treatment may cause fibrosis, the definitive treatment is generally a surgical resection of the affected bowel segment, enabling the histopathological examination of the resection material.

Management of ovarian endometriosis in middle-aged women

Progestins and COCs showed great success in the treatment of symptoms related to ovarian endometrioma during reproductive age and they are considered as first-line treatment until 50 years of age¹⁵. Surgery should be offered to symptomatic patients unresponsive to medical therapy independently of their age. The available evidence supports long-term medical therapy also after surgery to prevent recurrence of the disease and symptoms^{15,21}. However, in middle-aged women the risk of an occult malignancy in the endometriotic cyst represents a critical issue. Thus, the risks associated with surgery (complications, recurrences, surgical menopause) should be balanced with the risks associated with malignant transformation. Ovarian cystectomy represents the gold standard for the surgical treatment of an endometrioma, although in patients approaching menopause who have satisfied their pregnancy desire, bilateral salpingo-oophorectomy is a reasonable option to lower the risk of recurrences and ovarian cancer⁶.

Management of rare endometriosis: thoracic endometriosis syndrome and endometriosis involving the nervous system

Catamenial pneumothorax is primarily treated by definitively managing the presenting feature (e.g. chest tube drainage of pneumothorax) followed by secondary prevention of recurrences (e.g. blebectomy, pleurodesis, repair of diaphragmatic fenestrations followed by hormonal suppression)⁵⁵.

Consistent data on the management of thoracic endometriosis syndrome in the perimenopause period are lacking; five cases of thoracic endometriosis in women aged 40–50 years have been described^{51,56,57}. Four cases reported a right-sided pneumothorax (80%) that seems to be the most frequent side for location of thoracic endometriosis, while in one case (20%) pneumothorax has not been reported but thoracic endometriosis syndrome was associated with the presence of right-sided pleural effusion and

adhesions on the pleural surface with hemorrhagic spots⁵⁷. The thoracic location of endometriosis was associated with an intestinal endometriosis in 20% of the cases⁵⁶, while in another case the patient presented also adenomyosis, ovarian cyst, and ascites⁵⁷. Clinically, chest pain during menstrual period was present in four cases (80%) and other respiratory symptoms, such as breathlessness, cough, and chest discomfort, have also been frequently reported in association (60%). The complete absence of thoracic clinical symptoms has been reported in two cases (40%). The management included medical treatment, mostly with GnRH-a and progestins (medroxyprogesterone acetate, cyproterone), and surgical treatment, represented by pleurodesis and/or hysterectomy and salpingo-oophorectomy. Thus, according to experience and data from observational studies, patients affected should be treated with hormonal therapy (COCs or progestins) if there are no serious side effects. However, if recurrence occurs during hormonal therapy or side effects are intolerable, bilateral salpingo-oophorectomy is indicated.

Endometriosis involving the nervous system, or 'neuroendometriosis', is an infrequent finding. Seventeen cases of neurologic endometriosis diagnosed in perimenopausal age have been reported in 14 studies (Table 3)^{58–71}. Somatic nerves were involved in 15 of the women and the central nervous system was involved in two. Clinical management included surgical treatment, mostly represented by neurolysis and/or hysterectomy and salpingo-oophorectomy, and/or treatment with GnRH-a.

Malignant transformation of endometriosis lesions in middle-aged women

Malignant transformation of endometriosis is estimated to occur in about 0.7–1.6% of women affected by endometriosis, with the ovary being the primary site in 79% while extraovarian sites account for about 20% of cases⁷². Specific criteria are recognized for the malignant transformation of endometriosis⁷³.

Cases of malignant transformation of bladder endometriosis

There are only nine cases describing cancer from bladder endometriosis, with four cases being in perimenopause. The histological type was primarily clear cell carcinoma, while the endometrioid adenocarcinoma was the second most common²⁹ (Table 4)^{72,74–76}. A univocal treatment approach is lacking and there are no shared guidelines for adjuvant medical treatment, consequently the commonly used chemotherapy for ovarian cancer has always been appointed. Based on the few available data, it is not possible to determine whether bladder tumors originating from malignant transformation of urinary endometriosis have a better prognosis than primitive bladder tumors, but a case of tumor due to recurrence of the specific disease has yet to be reported.

Cases of malignant transformation of bowel endometriosis

Slavin *et al.*⁷⁷ described 23 cases of endometriosis-associated intestinal tumors, 10 of which were in perimenopausal age. All considered cases underwent surgical treatment with a subgroup following chemotherapy (three cases) or radiotherapy (two cases). The majority of patients survived with no evidence of disease whereas death occurred in four patients⁷⁷. Kobayashi *et al.*⁷⁸ reported the case of a 45-year-old woman previously diagnosed with endometriosis affected by an endometrioid adenocarcinoma of the rectosigmoid, and readily discussed all of the reported cases of endometriosis-derived intramural endometrioid adenocarcinomas (4 out of 14 cases in perimenopausal age). The median age of the cohort at diagnosis was 55 years (range 38–80 years). Twenty-two percent of the patients had been previously treated for endometriosis. Primary surgical treatment was considered the treatment of choice with complete resection of all disease and appropriate staging biopsies. Even if the use of adjuvant chemotherapy in advanced stage is controversial, platinum drugs and taxol were given in some cases. Most endometriosis-associated endometrioid carcinomas are low grade and limited to their site of origin, with a generally good prognosis⁷⁸.

Concerning high-grade endometriosis-associated stromal sarcoma (ESS), Chen *et al.*⁷⁹ described a tumor emerging in a 42-year-old woman with no history of endometriosis and reviewed another 10 cases reported in the literature, three of these in perimenopause. Optimal cytoreductive surgery with adjuvant radiotherapy was considered the optimal therapy for ESS, with better outcomes than surgery alone. High-grade ESS has a worse prognosis than low-grade ESS, with higher relapse rates, requiring a life-long follow-up⁸⁰.

Cases of malignant transformation of ovarian endometriosis

The risk of ovarian cancer appears particularly elevated among subjects with a long-standing (>10 years) history of ovarian endometriosis, women with recurrent endometriomas, or in the case of de-novo endometrioma in women aged >45 years⁶. Other potential risk factors for malignancy include endometrioma sized over 9 cm or rapid growth of the cyst⁸¹.

The treatment plan for each patient should undoubtedly be individualized based on the patient's symptoms, age, family history, and ultrasound appearance.

Guerrero *et al.*⁸² showed that sonographic characteristics of ovarian endometriomas vary with age. As age increases, multilocular cysts and cysts with papillations and other solid components become more common, while the 'typical' ground glass echogenicity of cyst fluid and tender mass on ultrasound scan become less common. Papillary projections and solid components have been demonstrated to increase the risk of malignancy, but these findings may also occur in benign endometriomas, especially in older women. Therefore, ultrasound diagnosis could be challenging in this

age group because of the most frequent 'atypical aspects'. However, malignant transformation exhibits characteristic features like the overall ovarian masses: the presence of a 'vascularized solid component' is usually highly accurate in discriminating between benign and malignant cysts⁸². When a malignancy is doubtful or suspected, surgery is considered as first-line treatment. Strict surveillance or surgery options should be discussed with perimenopausal women with small typical long-standing or recurrent endometriomas, especially when modifications of ultrasonographic cyst patterns occur⁶. If surgery is chosen in women not wishing conception, removal of the affected ovary/ovaries rather than cystectomy together with bilateral salpingectomy should be performed.

Cases of malignant transformation of thoracic and neurological endometriosis

A single case with malignant transformation of thoracic and neurological endometriosis in perimenopausal age has been described in the literature (Table 4)^{61,83}.

Conclusions

This state-of-the-art review aims for the first time to assess the benefits and safety of the various therapies that can direct endometriosis treatment decisions for women approaching menopause. The menopause age for women with endometriosis is presently poorly defined but safety represents a critical issue for these women because they may need long periods of treatments even during advanced reproductive years. Progestins seem effective in suppressing, but not curing, bladder, bowel, and thoracic endometriosis in women with a good control of symptoms. Hysterectomy with bilateral salpingo-oophorectomy is currently the definitive therapy for women who have completed their reproductive arc and for those with failed medical therapy. For ovarian endometriosis, strict surveillance or surgery with removal of the affected gonads should be considered in cases of long-standing or recurrent endometriomas, especially in the presence of modifications of ultrasonographic cyst patterns. Although malignant transformation is rare, cases in endometriosis women approaching menopause have been described.

Acknowledgements

All of the authors of the Endometriosis Treatment Italian Club (ETIC Group) conceived the study and discussed the evidence. Paola Viganò, Jessica Ottolina, Ludovica Bartiromo, and Massimo Candiani contributed to the first draft of the article; all authors revised the article and approved the final version.

Conflict of interest No potential conflict of interest in relation to this topic was reported by the authors.

Source of funding This research did not receive any specific grant from funding agencies in the public, commercial, or not-for-profit sectors.

ORCID

N. Berlanda  <http://orcid.org/0000-0002-1797-1984>
 L. Buggio  <http://orcid.org/0000-0002-1199-1888>
 L. Fedele  <http://orcid.org/0000-0001-6297-7165>
 M. P. Frattaruolo  <http://orcid.org/0000-0001-7288-0113>
 C. Massarotti  <http://orcid.org/0000-0003-1905-2786>
 E. Somigliana  <http://orcid.org/0000-0002-0223-0032>
 P. Viganò  <http://orcid.org/0000-0003-3674-5912>

References

- Vercellini P, Viganò P, Somigliana E, Fedele L. Endometriosis: pathogenesis and treatment. *Nat Rev Endocrinol* 2014;10:261–75
- Punnonen R, Klemi PJ, Nikkanen V. Postmenopausal endometriosis. *Eur J Obstet Gynecol Reprod Biol* 1980;11:195–200
- Gylfason JT, Kristjansson KA, Sverrisdottir G, et al. Pelvic endometriosis diagnosed in an entire nation over 20 years. *Am J Epidemiol* 2010;172:237–43
- Haas D, Chvatal R, Reichert B, et al. Endometriosis: a premenopausal disease? Age pattern in 42,079 patients with endometriosis. *Arch Gynecol Obstet* 2012;286:667–70
- Witt BR, Barad DH. Management of endometriosis in women older than 40 years of age. *Obstet Gynecol Clin North Am* 1993;20:349–63
- Vercellini P, Viganò P, Buggio L, et al. Perimenopausal management of ovarian endometriosis and associated cancer risk: when is medical or surgical treatment indicated? *Best Pract Res Clin Obstet Gynaecol* 2018; pii:S1521–6934(18)30035
- Somigliana E, Vercellini P, Viganò P, Ragni G, Crosignani PG. Should endometriomas be treated before IVF-ICSI cycles? *Hum Reprod Update* 2006;12:57–64
- Coccia ME, Rizzello F, Mariani G, et al. Ovarian surgery for bilateral endometriomas influences age at menopause. *Hum Reprod* 2011;26:3000–7
- Sanchez AM, Viganò P, Somigliana E, et al. The distinguishing cellular and molecular features of the endometriotic ovarian cyst: from pathophysiology to the potential endometrioma-mediated damage to the ovary. *Hum Reprod Update* 2014;20:217–30
- Viganò P, Somigliana E, Panina P, et al. Principles of phenomics in endometriosis. *Hum Reprod Update* 2012;18:248–59
- de Vries E, den Tonkelaar I, van Noord PA, et al. Oral contraceptive use in relation to age at menopause in the DOM cohort. *Hum Reprod* 2001;16:1657–62
- American College of Obstetricians and Gynecologists. Practice Bulletin No. 114: Management of Endometriosis. *Obstet Gynecol* 2010;116:223–36
- Namnoum AB, Hickman TN, Goodman SB, Gehlbach DL, Rock JA. Incidence of symptom recurrence after hysterectomy for endometriosis. *Fertil Steril* 1995;64:898–902
- Matorras R, Elorriaga MA, Pijoan JI, Ramón O, Rodríguez-Escudero FJ. Recurrence of endometriosis in women with bilateral adnexectomy (with or without total hysterectomy) who received hormone replacement therapy. *Fertil Steril* 2002;77:303–8
- Dunselman GAJ, Vermeulen N, Becker C, et al. ESHRE guideline: management of women with endometriosis. *Hum Reprod* 2014;29:400–12
- Leyland N, Casper R, Laberge P, et al. Endometriosis: diagnosis and management. *J Obstet Gynaecol Can* 2010;32:S1–S3
- Johnson NP, Hummelshoj L, Abrao MS, et al. Consensus on current management of endometriosis. *Hum Reprod* 2013;28:1552–68
- National Institute for Health and Care Excellence. Endometriosis: diagnosis and management (NICE guideline 37). 2017. <https://www.nice.org.uk/guidance/ng73>
- World Health Organization. *Medical eligibility criteria for contraceptive use*. 4th ed. Geneva, Switzerland: WHO; 2010
- Vercellini P, Pietropaolo G, De Giorgi O, et al. Treatment of symptomatic rectovaginal endometriosis with an estrogen-progestogen combination versus low-dose norethindrone acetate. *Fertil Steril* 2005;84:1375–87
- Vercellini P, Somigliana E, Daguati R, et al. Postoperative oral contraceptive exposure and risk of endometrioma recurrence. *Am J Obstet Gynecol* 2008;198:504
- Morelli M, Rocca ML, Venturella R, Mocchiari R, Zullo F. Improvement in chronic pelvic pain after gonadotropin releasing hormone analogue (GnRH-a) administration in premenopausal women suffering from adenomyosis or endometriosis: a retrospective study. *Gynecol Endocrinol* 2013;29:305–8
- Modugno F, Ness RB, Allen GO, et al. Oral contraceptive use, reproductive history, and risk of epithelial ovarian cancer in women with and without endometriosis. *Am J Obstet Gynecol* 2004;191:733–40
- Gemmell LC, Webster KE, Kirtley S, et al. The management of menopause in women with a history of endometriosis: a systematic review. *Hum Reprod Update* 2017;23:481–500
- Moen MH, Rees M, Brincat M, et al. EMAS position statement: managing the menopause in women with a past history of endometriosis. *Maturitas* 2010;67:94–7
- Westney OL, Amundsen CL, McGuire EJ. Bladder endometriosis: conservative management. *J Urol* 2000;163:1814–17
- Maccagnano C, Pellucchi F, Rocchini L, et al. Diagnosis and treatment of bladder endometriosis: state of the art. *Urol Int* 2012;89:249–58
- Kovoor E, Nassif J, Miranda-Mendoza I, Wattiez A. Endometriosis of bladder: outcomes after laparoscopic surgery. *J Minim Invasive Gynecol* 2010;17:600–4
- Leone Roberti Maggiore U, Ferrero S, Candiani M, et al. Bladder endometriosis: A systematic review of pathogenesis, diagnosis, treatment, impact on fertility, and risk of malignant transformation. *Eur Urol* 2017;71:790–807
- Barra F, Scala C, Biscaldi E, et al. Ureteral endometriosis: a systematic review of epidemiology, pathogenesis, diagnosis, treatment, risk of malignant transformation and fertility. *Hum Reprod Update* 2018;24:710–730
- Remorgida V, Ferrero S, Fulcheri E, Ragni N, Martin DC. Bowel endometriosis: presentation, diagnosis, and treatment. *Obstet Gynecol Surv* 2007;62:461–70
- Collins PG. Endometriosis as a cause of intestinal obstruction; a report of two cases. *Postgrad Med J* 1957;33:519–25
- Scalvini L. Acute intestinal occlusion caused by endometrioma of the terminal ileum. *Minerva Chir* 1959;30:768–74
- Midorikawa Y, Kubota K, Kubota K, et al. Endometriosis of the rectum causing bowel obstruction: a case report. *Hepatogastroenterology* 1997;44:706–9
- Fujimoto A, Osuga Y, Tsutsumi O, et al. Successful laparoscopic treatment of ileo-cecal endometriosis producing bowel obstruction. *J Obstet Gynaecol Res* 2001;27:221–3
- Amendolara M, Giarin P, Carluccio A, et al. Sigmoid occlusion due to endometriosis. A case report. *Chir* 2001;22:333–6
- Mussa FF, Younes Z, Tihan T, Lacy BE. Anasarca and small bowel obstruction secondary to endometriosis. *J Clin Gastroenterol* 2001;32:167–71
- Kupersmith JEE, Catania JJ, Patil V, Hertz BL. Large bowel obstruction and endometriosis. *Hospital Physician* 2001;37:46–8
- Varras M, Kostopanagiotou E, Katis K, et al. Endometriosis causing extensive intestinal obstruction simulating carcinoma of the sigmoid colon: a case report and review of the literature. *Eur J Gynaecol Oncol* 2002;23:353–7
- Sheikh HA, Krishnamurti U, Bhat Y, Rajendiran S. A 42-year-old woman with a 7-month history of abdominal pain. A, endometriosis involving ileocecal junction and 2 pericolonic lymph nodes; B, intranodal benign glandular inclusions. *Arch Pathol Lab Med* 2005;129:218–21
- Yildirim S, Nursal TZ, Tarim A, et al. Colonic obstruction due to rectal endometriosis: report of a case. *Turk J Gastroenterol* 2005;16:48–51

42. De Ceglie A, Bilardi C, Bianchi S, et al. Acute small bowel obstruction caused by endometriosis: a case report and review of the literature. *WJG* 2008;1:3430–4
43. Mourthé de Alvim Andrade M, Batista Pimenta M, de Freitas Belezia B, Duarte T. Rectal obstruction due to endometriosis. *Tech Coloproctol* 2008;12:57–9
44. Ruiz R, Pacheco M, Oliden O. Ileal endometriosis as cause of intestinal obstruction. A case presentation. *An Med Interna* 2008;25:307–8
45. de Jong MJ, Mijatovic V, van Waesberghe JH, Cuesta MA, Hompes PG. Surgical outcome and long-term follow-up after segmental colorectal resection in women with a complete obstruction of the rectosigmoid due to endometriosis. *Dig Surg* 2009;26:50–5
46. Caselli G, Besa C, Pulgar D. Intestinal obstruction as manifestation of a multifocal colonic endometriosis. *Clin Gastroenterol Hepatol* 2011;9:e90–1
47. Unalp HR, Akguner T, Yavuzcan A, Ekinici N. Acute small bowel obstruction due to ileal endometriosis: a case report and review of the most recent literature. *Vojnosanit Pregl* 2012;69:1013–16
48. Khwaja SA, Zakaria R, Carneiro HA, Khwaja HA. Endometriosis: a rare cause of small bowel obstruction. *BMJ Case Rep* 2012;13:2012
49. Soylu L, Sarikaya S, Aydin OY, Aydin S, Atalay F. Intestinal obstruction due to endometriosis; report of two cases report. *Turk J Colorectal Dis* 2012;22:30–3
50. Lanitis S, Korontzi M, Karaliotas C. Acute bowel obstruction in a premenopausal woman. *Gastroenterology* 2013;144:5–6
51. Azizad-Pinto P, Clarke D. Thoracic endometriosis syndrome: case report and review of the literature. *Perm J* 2014;18:61–5
52. Arafat S, Alsabek MB, Almousa F, Kubtan MA. Rare manifestation of endometriosis causing complete recto-sigmoid obstruction: a case report. *Int J Surg Case Rep* 2016;26:30–3
53. López Carrasco A, Hernández Gutiérrez A, Hidalgo Gutiérrez PA, et al. Ileocecal endometriosis: diagnosis and management. *Taiwan J Obstet Gynecol* 2017;56:243–6
54. Chan DL, Chua D, Ravindran P, Perez Cerdeira M, Mor I. A case report of endometriosis presenting as an acute small bowel obstruction. *Int J Surg* 2017;41:17–19
55. Korom S, Canyurt H, Missbach A, et al. Catamenial pneumothorax revisited: clinical approach and systematic review of the literature. *J Thorac Cardiovasc Surg* 2004;128:502
56. Oger P, Alifano M, Regnard JF, Gompel A. Difficult management of recurrent catamenial pneumothorax. *Gynecol Endocrinol* 2006;22:713–15
57. Nair SS, Nayar J. Thoracic endometriosis syndrome: A veritable Pandora's box. *J Clin Diagn Res* 2016;10:QR04–8
58. Richards BJ, Gillett WR, Pollock M. Reversal of foot drop in sciatic nerve endometriosis. *J Neurol Neurosurg Psychiatry* 1991;54:935–6
59. Zager EL, Pfeifer SM, Brown MJ, Torosian MH, Hackney DB. Catamenial mononeuropathy and radiculopathy: a treatable neuropathic disorder. *J Neurosurg* 1998;88:827–30
60. Vilos GA, Vilos AW, Haebe JJ. Laparoscopic findings, management, histopathology, and outcome of 25 women with cyclic leg pain. *J Am Assoc Gynecol Laparosc* 2002;9:145–51
61. Lacroix-Triki M, Beyris L, Martel P, Marques B. Low-grade endometrial stromal sarcoma arising from sciatic nerve endometriosis. *Obstet Gynecol* 2004;104:1147–9
62. Fatemi HM, Al-Turki HA, Papanikolaou EG, et al. Successful treatment of an aggressive recurrent post-menopausal endometriosis with an aromatase inhibitor. *Reprod Biomed Online* 2005;11:455–7
63. Nagra I, Stirling AJ, James SL. A 45-year-old woman with a presacral mass lesion: diagnosis and discussion. *Skeletal Radiol* 2010;39:183–4
64. Floyd JR, Keeler ER, Euscher ED, McCutcheon IE. Cyclic sciatica from extrapelvic endometriosis affecting the sciatic nerve. *J Neurosurg Spine* 2011;14:281–9
65. Ceccaroni M, Clarizia R, Cosma S, et al. Cyclic sciatica in a patient with deep monolateral endometriosis infiltrating the right sciatic nerve. *J Spinal Disord Tech* 2011;24:474–8
66. Ghezzi L, Arighi A, Pietrobboni AM, et al. Sciatic endometriosis presenting as periodic (catamenial) sciatic radiculopathy. *J Neurol* 2012;259:1470–1
67. Siquara De Sousa AC, Capek S, Amrami KK, Spinner RJ. Neural involvement in endometriosis: review of anatomic distribution and mechanisms. *Clin Anat* 2015;28:1029–38
68. Capek S, Amrami KK, Howe BM, et al. Sequential imaging of intra-neural sciatic nerve endometriosis provides insight into symptoms of cyclical sciatica. *Acta Neurochir (Wien)* 2016;158:507–12
69. Arányi Z, Polyák I, Tóth N, Vermes G, Göcsei Z. Ultrasonography of sciatic nerve endometriosis. *Muscle Nerve* 2016;54:500–5
70. Sarma D, Iyengar P, Marotta TR, et al. Cerebellar endometriosis. *Am J Roentgenol* 2004;182:1543–6
71. Agrawal A, Shetty BJ, Makannavar JH, et al. Intramedullary endometriosis of the conus medullaris: case report. *Neurosurgery* 2006;59:E428
72. Tarumi Y, Mori T, Kusuki I, Ito F, Kitawaki J. Endometrioid adenocarcinoma arising from deep infiltrating endometriosis involving the bladder: A case report and review of the literature. *Gynecol Oncol Rep* 2015;13:68–70
73. Scott RB. Malignant changes in endometriosis. *Obstet Gynecol* 1953;2:283–9
74. Balat O, Kudelka AP, Edwards CL, Silva E, Kavanagh JJ. Malignant transformation in endometriosis of the urinary bladder: case report of clear cell adenocarcinoma. *Eur J Gynaecol Oncol* 1996;17:13–16
75. Mann S, Patel P, Matthews CM, Pinto K, O'Connor J. Malignant transformation of endometriosis within the urinary bladder. *Proc Bayl Univ Med Cent* 2012;25:293–5
76. Miller EM, Sun Y, Richardson I, Frimer M. Vesical clear cell adenocarcinoma arising from endometriosis: a mullerian tumor, indistinguishable from ovarian clear cell adenocarcinoma. *Gynecol Oncol Rep* 2016;18:8–10
77. Slavin RE, Krum R, Van Dinh T. Endometriosis-associated intestinal tumors: a clinical and Pathological Study of 6 Cases With a review of the literature. *Hum Pathol* 2000;31:456–63
78. Kobayashi S, Sasaki M, Goto T, et al. Endometrioid adenocarcinoma arising from endometriosis of the rectosigmoid. *Dig Endosc* 2010;22:59–63
79. Chen CW, Qu JJ, Wu CC, Hsiao CW, Cheng MF, Jao SW. High-grade endometrial stromal sarcoma arising from colon endometriosis. *Int J Colorectal Dis* 2007;22:1551–3
80. Lan C, Huang X, Lin S, Cai M, Liu J. Endometrial stromal sarcoma arising from endometriosis: a clinicopathological study and literature review. *Gynecol Obstet Invest* 2012;74:288–97
81. Kobayashi H, Sumimoto K, Kitanaka T, et al. Ovarian endometrioma—risks factors of ovarian cancer development. *Eur J Obstet Gynecol Reprod Biol* 2008;138:187–93
82. Guerriero S, Van Calster B, Somigliana E, et al. Age-related differences in the sonographic characteristics of endometriomas. *Hum Reprod* 2016;31:1723–31
83. Yu JH, Lin XY, Wang L, et al. Endobronchial endometriosis presenting as central-type lung cancer: a case report. *Diagn Pathol* 2013;8:53