

Successful achievement after heterotopic transplantations of long-term stored ovarian tissue in Hodgkin's lymphoma survivor

R. Fabbri, R. Seracchioli, R. Vicenti, R. Paradisi, S. Rossi, L. De Meis, M. Ciccarone, G. Caprara, N. A. Martino & M. Macciocca

To cite this article: R. Fabbri, R. Seracchioli, R. Vicenti, R. Paradisi, S. Rossi, L. De Meis, M. Ciccarone, G. Caprara, N. A. Martino & M. Macciocca (2019) Successful achievement after heterotopic transplantations of long-term stored ovarian tissue in Hodgkin's lymphoma survivor, *Gynecological Endocrinology*, 35:6, 470-472, DOI: [10.1080/09513590.2018.1549218](https://doi.org/10.1080/09513590.2018.1549218)

To link to this article: <https://doi.org/10.1080/09513590.2018.1549218>



Published online: 02 Jan 2019.



Submit your article to this journal [↗](#)



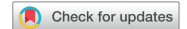Article views: 74



View Crossmark data [↗](#)



Citing articles: 1 View citing articles [↗](#)



Successful achievement after heterotopic transplantations of long-term stored ovarian tissue in Hodgkin's lymphoma survivor

R. Fabbri^{a*}, R. Seracchioli^{a*}, R. Vicenti^a, R. Paradisi^a, S. Rossi^b, L. De Meis^b, M. Ciccarone^c, G. Caprara^d, N. A. Martino^e and M. Macciocca^a

^aGynecology and Physiopathology of Human Reproduction Unit, Department of Medical and Surgical Sciences, University of Bologna S. Orsola-Malpighi Hospital of Bologna, Bologna, Italy; ^bGynecology and Physiopathology of Human Reproduction Unit, S. Orsola-Malpighi Hospital of Bologna, Bologna, Italy; ^cDepartment of Gynecology, San Carlo di Nancy Hospital, Rome, Italy; ^dDepartment of Histopathological and Molecular Diagnostic Unit of Solid Organ and Transplant, S. Orsola-Malpighi Hospital of Bologna, Bologna, Italy; ^eDepartment of Biosciences, Biotechnologies and Biopharmaceutics, University of Bari Aldo Moro, Bari, Italy

ABSTRACT

In this case report, we describe the outcomes of two heterotopic transplantations of cryopreserved ovarian tissue performed in a patient with HL, after 11 and 15 years of storage. At the age of 30, the patient underwent laparoscopy to collect ovarian tissue for cryopreservation before chemotherapy and radiotherapy. Eleven years later she experienced premature ovarian failure (POF). As the patient was only interested in endocrine function recovery, two heterotopic ovarian tissue transplantations were performed in the abdominal wall above the rectus muscle respectively 11 and 15 years after cryopreservation. Before transplantation, ovarian samples were analyzed to assess neoplastic contamination and tissue quality. The analysis on thawed ovarian tissue did not reveal micrometastasis and it showed well-preserved follicles and stroma. After both ovarian tissue grafting, menopausal symptoms ceased. The patient had periods approximately every 30-days and hormonal levels were within the premenopausal range. The endocrine function lasted 3-years after the first heterotopic transplantation and is still ongoing after second transplantation. Cryopreservation of ovarian tissue should be proposed to HL patients, as the incidence of POF as a long-term complication is not negligible. In these patients heterotopic transplantation is a useful tool to eliminate menopausal symptoms, preventing osteoporosis and reducing cardiovascular risks.

ARTICLE HISTORY

Received 8 March 2018
Accepted 13 November 2018
Published online 3 January 2019

KEYWORDS

Ovarian tissue cryopreservation; fertility preservation; heterotopic transplantation; ovarian function recovery; Hodgkin's lymphoma

Introduction

Recent advances in cancer diagnosis and the introduction of new chemotherapy and radiotherapy protocols have significantly increased the survival rates of children, adolescents and young adults with cancer. However, these treatments are gonadotoxic and can severely affect or totally destroy the reproductive potential of patients [1]. Up to two-thirds of young adult female patients receiving chemotherapy for malignancies eventually develop premature ovarian failure (POF) [2]. This risk varies from under 10% to over 95% depending on different factors: patient's age, ovarian reserve before treatment, type and cumulative dose of chemotherapy [3].

The increase in cancer incidence in young women and the significant improvement in permanent remission have led to a growing interest in long-term health and quality of life.

Ovarian tissue cryopreservation is a valid strategy to preserve reproductive function and steroidogenic activity in patients at risk of POF. After thawing, the ovarian cortical strips can be grafted into the orthotopic site, the ovary, allowing the recovery of endocrine function and spontaneous pregnancy or into the heterotopic site, the subcutaneous space of the abdominal wall, allowing recovery of endocrine function [4]. To date, the outcomes obtained after cryopreserved ovarian tissue transplantation

are very encouraging: the recovery of ovarian function is 95% and more than 130 successful births are reported [1].

Hodgkin's lymphoma (HL) is the most frequent malignancy in children, adolescents and young adults (37 per million cases recently diagnosed in patients aged 15–19 and 50 per million in patients aged 20–29) [5]. The HL prognosis is age-related with 15-year survival rates of 94, 91, and 87% in age groups of 18–29, 30–39, and 40–49 years, respectively. Prognosis also depends on disease stage, risk factors and therapeutic responses [6].

Here we describe the outcomes of two heterotopic transplantations of cryopreserved ovarian tissue performed in a patient with HL, after 11, and 15 years of storage.

Case report

In 2000, at 30, the patient was investigated for a serotine fever, retrosternal pain, and swelling in the left latero-cervical site. The magnetic resonance imaging showed the presence of parenchymatous retroperitoneal masses. The supraclavicular lymphnode biopsy confirmed the diagnosis of HL stage II. After signed written informed consent, a laparoscopy was performed to collect ovarian tissue for cryopreservation, in case of POF after treatments [1]. Subsequently, the patient received six cycles of ABVD

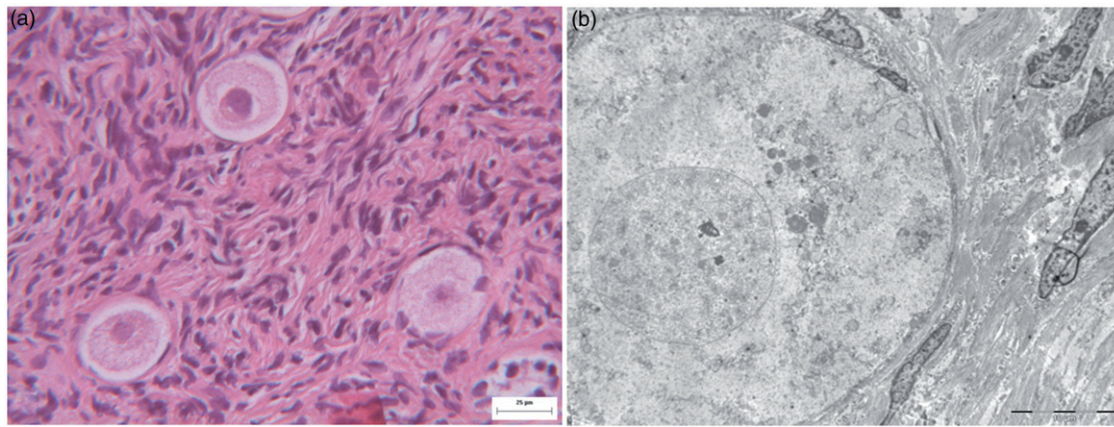


Figure 1. Thawed ovarian tissue: (A) histological appearance of follicles showed oocytes with regular cytoplasm and well-preserved stroma without vacuolization or edema (Bar 25 μ m). (B) Ultrastructural image of oocyte nuclei with a regular shape, dispersed chromatin and intact nuclear membrane, perinuclear cluster of mitochondria with normal matrices, and cytoplasm with homogeneous texture. The granulosa cells also showed normal chromatin pattern and cytoplasm density. The stromal cells showed dispersed chromatin or small chromatin clumps at the nuclear periphery and cytoplasm fragmentation (Bar 10 μ m).

and supradiaphragmatic radiotherapy. After the treatments, the patient had regular menstrual cycles for nine years, followed by severe oligomenorrhea that hesitated in amenorrhea in 2011, with pronounced menopausal symptoms (hot flushing and tendency to osteoporosis). Eleven years after cryopreservation, the patient requested ovarian tissue autotransplantation. The patient underwent computerized tomography (CT) to confirm complete remission of the primary lesion, hormonal evaluation, and ultrasound examination to confirm menopausal status. The CT scan revealed no relapse of disease; hormonal assays showed FSH 123 mIU/ml, LH 46mIU/ml, progesterone (P) 0.17 ng/ml and estradiol (E_2) <12 pg/ml; and atrophic ovaries were evidenced by ultrasound examination.

A fragment of thawed ovarian tissue was analyzed by immunohistochemical, histological, and ultrastructural analysis in order to assess neoplastic contamination, follicular density, and tissue quality. Immunohistochemical analysis for anti-CD30 and anti-ki67 antibodies revealed no Reed–Sternberg cells in thawed ovarian tissue. The follicles showed oocytes with regular cytoplasm and well-preserved stroma without vacuolization or edema (Figure 1(A)). The follicular density was nine follicles per mm^2 . Ultrastructural analysis showed a normal morphology after thawing: oocyte nuclei with a regular shape dispersed chromatin and intact nuclear membrane, a perinuclear cluster of mitochondria with normal matrices, and cytoplasm with homogeneous texture. The granulosa cells also showed normal chromatin pattern and cytoplasm density. The stromal cells showed dispersed chromatin or small chromatin clumps at the nuclear periphery and cytoplasm fragmentation (Figure 1(B)).

As the patient was only interested in endocrine function recovery, heterotopic ovarian tissue transplantation was performed. On the day of transplantation, 12 cortical strips were thawed and sutured into two small pockets of the abdominal wall above the rectus muscle (Figure 2(A)). After transplantation, ovarian function was monitored by hormonal assay, ultrasound examination at \sim 4 week intervals. Sixteen weeks after ovarian tissue grafting, menopausal symptoms ceased and the patient reported bulges in the transplantation areas (Figure 2(B)). The hormonal levels were: FSH 8 mIU/ml, LH 10mIU/ml, P 0.33 ng/ml, and E_2 488 pg/ml. Follicular development was observed in both graft sites: 5 follicles (3, 4, 5, 5, 6 mm) in the right graft and 3 follicles (4, 4, 5 mm) in the left graft. The first spontaneous menstruation appeared 21 weeks after transplantation. For about 3 years, the patient had periods approximately every 30 days,

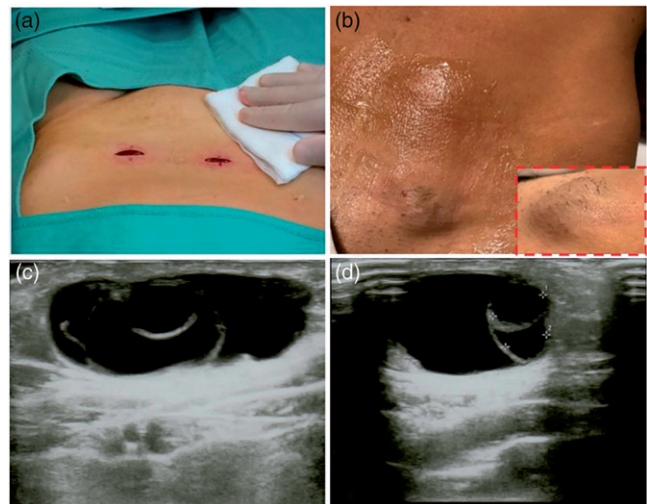


Figure 2. Surgical techniques of (A) heterotopic transplantation in two pockets created in the abdominal wall above the rectus muscle. (B) Bulge observed in the transplantation areas sixteen weeks after ovarian tissue grafting. (C) Transabdominal ultrasound showing numerous follicles in the heterotopic site twelve weeks after second transplantation. (D) Detail of transabdominal ultrasound showing three 17, 6 and 5-mm diameter follicles in the heterotopic site.

with the normal menstrual flow, hormonal levels (FSH, LH, P, and E_2) within the premenopausal range and follicular development in the graft sites. Bone densitometry values were improved after ovarian tissue transplantation. Thirty-eight months after grafting, the menstrual cycles stopped. Ultrasound examination showed atrophic ovaries, homogeneous ovarian tissue implant in one pocket and a 4-mm-follicle in the other pocket. Hormonal evaluation showed postmenopausal levels: FSH 89 mIU/ml, LH 23mIU/ml, E_2 <12 pg/ml, P 0.16 ng/ml.

Based on the great benefits obtained in the quality of life (disappearance of menopausal symptoms and reduction of osteoporosis) the patient requested a second transplantation that was performed after a few months later using tissue stored for 15 years. In the second heterotopic transplantation, ten cortical strips were thawed and sutured in the same two small pockets of the abdominal wall, previously created. The resumption of endocrine function after the second transplantation was faster: after 3 months the patient had the first menstrual cycle, FSH, and LH

levels dropped to 7 and 9 mIU/ml, respectively, E₂ increased to 368 pg/ml and *p* values were 0.28 ng/ml. Follicular development was observed in both subcutaneous graft sites: 6 follicles (17, 8, 6, 5, 3, 2 mm) in the right graft and 2 follicles (5, 5 mm) in the left ones (Figure 2(C,D)). To date (24 months after the second transplantation), patient monitoring is still ongoing, menstrual cycles are regular, hormonal levels (FSH, LH, P, and E₂) are within the normal range and follicular development in the graft sites is still present.

Discussion

Fertility preservation techniques have become an established component of oncology. The FertiPROTEKT network has recently published the practical recommendations for fertility preservation in women affected by HL. For women with a low or moderate POF risk, GnRH agonists, oocyte cryopreservation following ovarian hyperstimulation and ovarian tissue cryopreservation are adequate options for fertility preservation [6].

The most important finding of our study is the recovery of ovarian function after heterotopic transplantation of ovarian tissue stored for 11 and 15 years, providing the real proof that storage time does not impact on tissue preservation and ovarian function recovery. In addition, a recent report describes the birth of a healthy baby from ovarian tissue cryopreserved during childhood and stored for 10 years [7]. Furthermore, Fabbri et al in 2016 demonstrated that ovarian tissue stored for 18 years maintained the *in vitro* morpho-functional integrity [8]. The data are very reassuring for oncological patients that cryopreserve ovarian tissue before starting chemo and radiotherapy treatments and especially for prepubertal girls who will keep their ovarian tissue stored for a long time.

This case report shows that 11 years after cryopreservation, at 41 the patient developed POF, reflecting the early depletion of oocytes caused by gonadotoxic treatments. She requested autotransplantation to counteract menopausal symptoms (hot flushing and osteoporosis). As a matter of fact, as suggested in the literature, the risk of POF as a long-term complication associated to cancer treatments is more common than earlier estimated: after an observation time of 15 years, the cumulative risk of POF is 38% independent of age at the time of therapies [9].

As the recovery of endocrine function lasted 3 years after the first heterotopic transplantation and to date is still ongoing, the patient had remarkable benefits on the quality of life showing an improvement of emotional, psychological, and somatic symptoms.

Heterotopic transplantation shows several advantages: it avoids invasive procedures (such as laparoscopy) and it is easy to monitor and it permits the restoration of ovarian function in high percentage of grafts [10]. Moreover a single case of twins born after heterotopic transplantation associated with *in vitro* fertilization [11].

Ovarian tissue survival after transplantation varies from a few months to 7 years, as demonstrated by Kim et al [12]. Several factors can affect the longevity of ovarian grafts which include the cryopreservation method, the surgical technique transplantation, the number and size of grafted ovarian tissue, the degree of ischemia after transplantation, the number of survived follicles in ovarian graft, the age and ovarian reserve of patient at the time of ovarian tissue cryopreservation [12].

Ovarian tissue should be grafted in a very vascularized site. Data from literature identifies the space above the rectus muscle as the best site of heterotopic transplantation, because it is

vascularized to facilitate angiogenesis and to minimize ischemia damage, that causes follicular loss [10].

Conclusions

Cryopreservation of ovarian tissue should be proposed to HL patients, as the incidence of POF as long-term complication is not negligible. In these patients, heterotopic transplantation is a useful tool to eliminate menopausal symptoms without causing or exacerbating other health risks. With a broader clinical perspective, heterotopic transplantation could potentially save enormous health care costs, preventing osteoporosis and reducing cardiovascular risks.

Consent

The patient has given written consent for publication of this case.

Acknowledgements

The authors thank the native speaker Danielle Calandrino for the English revision of the manuscript.

Disclosure statement

No potential conflict of interest was reported by the authors.

References

- [1] Donnez J, Dolmans MM. Fertility preservation in women. *N Engl J Med*. 2017;377:1657–1665.
- [2] Bedaiwy MA, Abou-Setta AM, Desai N, et al. Gonadotropin-releasing hormone analog cotreatment for preservation of ovarian function during gonadotoxic chemotherapy: a systematic review and meta-analysis. *Fertil Steril*. 2011;95:906–14.e1-4.
- [3] Garrido-Oyarzún MF, Castelo-Branco C. Controversies over the use of GnRH agonists for reduction of chemotherapy-induced gonadotoxicity. *Climacteric*. 2016;19:522.
- [4] Fabbri R, Pasquinelli G, Magnani V, et al. Autotransplantation of cryopreserved ovarian tissue in oncological patients: recovery of ovarian function. *Future Oncol*. 2014;10:549–561.
- [5] Kahn JM, Ozuah NW, Dunleavy K, et al. Adolescent and young adult lymphoma: collaborative efforts toward optimizing care and improving outcomes. *Blood Adv*. 2017;1:1945–1958.
- [6] Schüring AN, Fehm T, Behringer K, et al. Practical recommendations for fertility preservation in women by the FertiPROTEKT network. Part I: indications for fertility preservation. *Arch Gynecol Obstet*. 2018;297:241–255.
- [7] Demeestere I, Simon P, Dedeken L, et al. Live birth after autograft of ovarian tissue cryopreserved during childhood. *Hum Reprod*. 2015;30:2107.
- [8] Fabbri R, Macciocca M, Vicenti R, et al. Long-term storage does not impact the quality of cryopreserved human ovarian tissue. *J Ovarian Res*. 2016;9:1–10.
- [9] Haukvik UK, Dieset I, Bjørø T, et al. Treatment-related premature ovarian failure as a long-term complication after Hodgkin's lymphoma. *Ann Oncol*. 2006;17:1428–1433.
- [10] Kim SS. Revisiting the role of heterotopic ovarian transplantation: fertility or fertility. *Reprod Biomed Online*. 2014;28:141–145.
- [11] Stern CJ, Gook D, Hale LG, et al. Delivery of twins following heterotopic grafting of frozen-thawed ovarian tissue. *Hum Reprod*. 2014;29:1828.
- [12] Kim SS. Assessment of long term endocrine function after transplantation of frozen-thawed human ovarian tissue to the heterotopic site: 10 year longitudinal follow-up study. *J Assist Reprod Genet*. 2012;29:489–493.